

Pulmonary Function and High-Resolution CT Findings in Patients With an Inherited Form of Pulmonary Fibrosis, Hermansky-Pudlak Syndrome, Due to Mutations in *HPS-1**

Mark Brantly, MD; Nilo A. Avila, MD; Vorasuk Shotelersuk, MD;
Cynthia Lucero, BA; Marjan Huizing, PhD; and William A. Gahl, MD, PhD

Objective: To describe and correlate pulmonary function and high-resolution CT (HRCT) scan scores in individuals with a high risk for development of pulmonary fibrosis, *ie*, Hermansky-Pudlak syndrome (HPS) patients with mutations in the *HPS-1* gene.

Design: Cross-sectional analysis of consecutive, eligible patients.

Patients: Thirty-eight HPS inpatients at the National Institutes of Health Clinical Center with *HPS-1* mutations.

Results: Thirty-seven patients were Puerto Rican and exhibited the typical 16-base pair (bp) duplication in exon 15 of *HPS-1*. One non-Puerto Rican was homozygous for a different mutation (intervening sequence 17 -2 A→C) previously reported in the *HPS-1* gene; he died at age 35 of pulmonary insufficiency. For the 23 patients who had pulmonary symptoms, the mean age of onset was 35 years. For all 38 patients (mean age, 37 ± 2 years), the mean FVC was 71% of predicted; the mean FEV₁, 76%; mean total lung capacity (TLC), 72%; mean vital capacity (VC), 68%; and mean diffusing capacity of the lung for carbon monoxide (DLCO), 72%. When patients were grouped according to the extent of their reduction in FVC, the other four pulmonary function parameters followed the FVC. Seventeen patients had abnormal chest radiographs, and 31 (82%) had abnormal HRCT scans of the chest, for which a scoring system of 0 (normal) to 3 (severe fibrosis) is presented. The mean ± SEM HRCT score for 38 patients was 1.30 ± 0.17. HRCT scores correlated inversely with FVC and DLCO.

Conclusions: Mutations in the *HPS-1* gene, whether or not they involve the typical 16-bp duplication seen in Puerto Rican patients, are associated with fatal pulmonary fibrosis. In affected patients, the FVC, FEV₁, TLC, VC, and DLCO fall in concert, and this functional deficit correlates with HRCT scan evidence of progression of interstitial lung disease.

(*CHEST* 2000; 117:129-136)

Key words: albinism; CT scans; pulmonary fibrosis; pulmonary function tests

Abbreviations: cDNA = complementary DNA; DLCO = diffusing capacity of the lung for carbon monoxide; HPS = Hermansky-Pudlak syndrome; HRCT = high-resolution CT; IVS = intervening sequence; NIH = National Institutes of Health; PCR = polymerase chain reaction; TLC = total lung capacity; VC = vital capacity

Hermansky-Pudlak syndrome (HPS) is an autosomal recessive disease characterized by oculocutaneous albinism, a platelet storage pool deficiency, and lysosomal accumulation of ceroid lipofuscin.^{1,2}

*From the Clinical Studies Section, Pulmonary-Critical Care Medicine Branch, National Heart, Lung, and Blood Institute (Dr. Brantly), the Warren G. Magnuson Clinical Center, Diagnostic Radiology Department (Dr. Avila), and the Section on Human Biochemical Genetics, Heritable Disorders Branch (Drs. Shotelersuk, Huizing, and Gahl, and Ms. Lucero), National Institute of Child Health and Human Development, National Institutes of Health, Bethesda, MD.
Manuscript received May 13, 1999; revision accepted August 10, 1999.

Correspondence to: William A. Gahl, MD, PhD, 10 Center Dr, MSC 1830, Building 10, Room 9S-241, NICHD, NIH, Bethesda, MD 20892-1830; e-mail: bgahl@helix.nih.gov

The albinism manifests as congenital nystagmus, iris transillumination, decreased visual acuity, and widely variable hypopigmentation of the skin and hair.^{3,4} The platelet storage pool deficiency causes bruising and prolonged bleeding due to an impaired secondary aggregation response; electron microscopic evidence of absent platelet dense bodies provides the *sine qua non* for diagnosing HPS.⁵ Ceroid lipofuscin consists of a lipid-protein complex of unknown composition thought to accumulate in cellular lysosomes and believed to cause pulmonary fibrosis^{6,7} and granulomatous colitis^{8,9} in some patients. In affected individuals, the pulmonary fibrosis typically leads to death in the fourth or fifth decade.² Although HPS occurs worldwide, it is most common in northwest

Reprinted from *CHEST*

Vol. 117, p. 129-136, January 2000 Issue

Puerto Rico, where its frequency is 1 in 1,800¹⁰ owing to a founder effect.

In 1995, a gene causing HPS was mapped to chromosome 10q23.1–23.3 by linkage analysis in the Puerto Rican population.^{11,12} In 1996, the gene, now referred to as *HPS-1*, was identified and sequenced,¹³ and its intron/exon organization was later characterized.¹⁴ *HPS-1* has 20 exons coding for a 700-amino acid, 79.3-kd protein that is ubiquitously expressed but has no recognized function and no homology to known proteins. To date, 12 different *HPS-1* mutations have been identified among Puerto Ricans and non-Puerto Ricans.^{13,15–18} A homozygous 16-base pair (bp) duplication in exon 15 of *HPS-1* has been found in all HPS patients from northwest Puerto Rico but in no non-Puerto Rican patients.^{13,15,16,19} The absence of *HPS-1* mutations in *bona fide* HPS patients points to locus heterogeneity in both the Puerto Rican¹⁹ and non-Puerto Rican^{15,16} populations.

We previously demonstrated that Puerto Rican patients homozygous for the 16-bp duplication carry an increased risk for developing restrictive pulmonary disease.²⁰ To further investigate the pulmonary fibrosis associated with HPS, we performed pulmonary function studies and high-resolution CT (HRCT) scans of the chest in 38 patients with mutations in *HPS-1*. Pulmonary function results were correlated with radiographic evidence of fibrosis, and the natural history of pulmonary dysfunction in patients with *HPS-1* mutations was documented. We also provide evidence that *HPS-1* mutations in general, rather than homozygosity for the 16-bp duplication specifically, constitute the risk factor for pulmonary fibrosis.

MATERIALS AND METHODS

Patients

All the subjects were enrolled in a protocol approved by the National Institute of Child Health and Human Development Institutional Review Board and all gave written informed consent. HPS was diagnosed based on the presence of oculocutaneous albinism and a bleeding diathesis; the diagnosis was confirmed on molecular grounds. To be included in this data analysis, patients were required to be adults admitted to the National Institutes of Health (NIH) Clinical Center, to have mutations in *HPS-1*, and to have undergone an HRCT scan of the lung. Thirty-eight individuals met these criteria between January 1996 and June 1998.

Molecular Studies

Genomic DNA, extracted from peripheral leukocytes or fibroblasts using a standard procedure,²¹ served as a template for polymerase chain reaction (PCR) amplification to detect the 16-bp duplication in exon 15 of *HPS-1*. Primers and conditions

were as previously described.^{13,15,19} When electrophoresed in 3% agarose and stained with ethidium bromide, the 285-bp product of the duplication patients was easily distinguishable from the normal, 269-bp product.

Both complementary DNA (cDNA) and genomic DNA were employed to detect the *HPS-1* mutation in the non-Puerto Rican patient. Reverse transcription PCR was performed after total RNA extraction from cultured fibroblasts using Trizol reagent (Life Technologies, Inc; Grand Island, NY). cDNA was synthesized by reverse transcription using 5 µg of total RNA, according to the protocol of the manufacturer (GIBCO-BRL; Grand Island, NY). The 2.1-kilobase coding region of the *HPS-1* cDNA was amplified using primers 5'-TGCAGCCCTTTCTGAACCTCTG-3' (forward) and 5'-GAACAGTGGCAAGCAAGGCTG-3' (reverse). PCR amplification was performed using 2 µL of the first stand cDNA, 1× PCR buffer, 1.5 mM MgCl₂, 200 µmol/L dGTP, 200 µmol/L dATP, 200 µmol/L dTTP, 200 µmol/L dCTP, 0.2 µmol/L primers, and 2.5 U *Taq* DNA polymerase in a final volume of 50 µL. After an initial denaturation step at 94°C for 4 min, PCR amplification was conducted for 35 cycles with a denaturation step at 94°C for 30 s, annealing at 55°C for 40 s, extension at 72°C for 2.5 min, and a final elongation step at 72°C for 10 min. Sequencing was performed using primers reported in Table 1 of the publication by Hazelwood et al.¹⁹ specifically, HP-1 (reverse), HP-2 (forward), HP-3 (forward), HP-4 (forward), HP-5 (forward), HP-6 (forward), and HP-7 (forward). Genomic DNA also served as a template for PCR amplification of the individual exons of *HPS-1*. The primers and conditions for genomic DNA were as previously described.^{14–16}

Direct, automated DNA sequencing was performed using the ABI Prism dRhodamine Terminator Cycle Sequencing Kit (Applied Biosystems; Foster City, CA) according to the manufacturer's recommendations.

Pulmonary Function Tests

Pulmonary function was assessed as previously described,²² using well-established normal values.

HRCT of the Chest

HRCT of the chest was performed on a GE Hispeed Advantage scanner (GE Medical Systems; Waukesha, WI) with the patient prone. The thorax was divided into upper, middle, and lower segments, and HRCT findings in each segment were recorded. HRCT scores were based on the following scheme: 0 = normal CT; 1 = mild disease (1 to 15 thickened interlobular septa per segment, one to five patches of reticulation, subpleural cysts, and pleural/parenchymal scars); 2 = moderate disease (moderate reticulation, peribronchovascular thickening, traction bronchiectasis, tracheal retraction); 3 = severe disease (areas of parenchymal consolidation, diffuse areas of peribronchovascular thickening, traction bronchiectasis, and patches of reticulation). Examples of HRCT scans corresponding to each score are shown in Figure 1. Two physicians (M.B. and N.A.A.) assigned CT scores at increments of 0.5 in a masked fashion, and the mean value was designated the subject's HRCT score. The mean difference in scores of the two readers was 0.5, and the inter-reader correlation coefficient was 0.77. The intra-reader correlation coefficient was 0.92.

Statistical Analysis

The lines in Figure 2 were determined using the least-squares method to calculate the best straight line fit. Routine definitions of the SEM and correlation coefficients were employed.

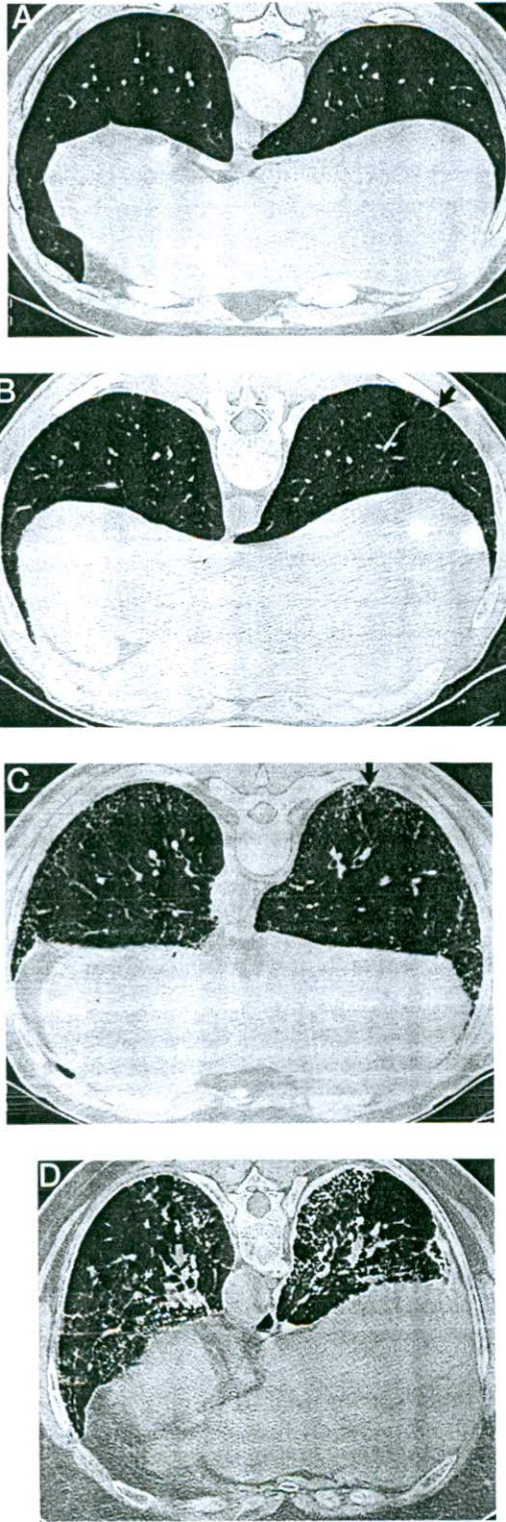


FIGURE 1. Typical HRCT scans through the lower lungs of HPS patients, showing progressively increasing scores. *Top, A*: no evidence of interstitial lung disease in a 27-year-old man (score = 0). *Top, B*: mild fibrosis (score = 1) in a 25-year-old man. Note thickened interlobular septum (arrow). *Bottom, C*: moderate fibrosis (score = 2) in a 53-year-old man. Note moderate peripheral reticulation (arrow). *Bottom, D*: severe fibrosis (score = 3) in a 53-year-old woman. Note reticular patches, bronchiectasis, peribronchovascular thickening (arrow), and subpleural cysts. See Materials and Methods for description of findings.

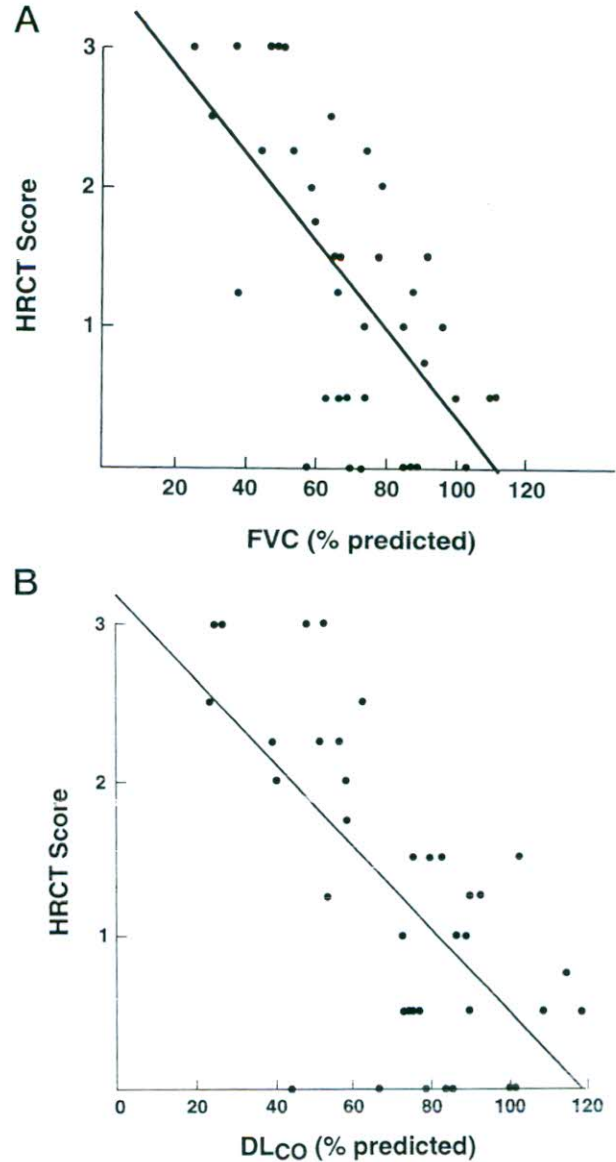


FIGURE 2. HRCT score as a function of FVC (*top, A*) and DLCO (*bottom, B*) in HPS patients. Lines represent the best least-squares fits for the data ($r = -0.66$ for each line).

RESULTS

Patient Population

Patient characteristics are shown in Table 1. The 38 HPS patients in this study ranged in age from 19 to 57 years, with a mean age of 37 years. Eighteen patients were men, and 37 were of Puerto Rican ancestry. All 37 Puerto Rican patients exhibited homozygosity for the typical 16-bp duplication in exon 15 of *HPS-1* (data not shown). Only 1 of the 38 patients smoked at the time of admission, but 5 had smoked sometime in their lives. The five had smoking histories estimated to be 2, 4, 14, 17, and 21 pack-years. Of the 38 patients, 23 had pulmonary

Table 1—Characteristics of HPS Study Population

Characteristics	No. of Patients	Mean	SEM
Age, yr	38	37.1	1.7
Puerto Ricans*	37		
Males	18		
Any prior smoking	5		
Age at first pulmonary symptoms, yr	23	35.1	2.1
Age at death, yr	5	37.2	1.2
FVC, % predicted	38	70.6	3.4
FEV ₁ , % predicted	38	76.2	3.5
TLC, % predicted	38	72.2	3.4
VC, % predicted	38	68.1	3.5
DLCO, % predicted	37	72.1	4.0
Oxygen saturation, %	31	96.6	0.5
Abnormal chest radiograph†	17		
HRCT score	38	1.30	0.17

*All 37 Puerto Rican patients were homozygous for the 16-bp duplication in exon 15 of *HPS-1*.

†Routine chest radiographs were obtained for 35 of the 38 patients.

symptoms, with a mean age of onset of 35.1 years (Table 1) and a range of 15 to 53 years. Five of our 38 patients have died, at a mean age of 37 years; 2 of the 5 had 14- and 21-pack-year histories of smoking.

The sole non-Puerto Rican patient exhibited a known mutation¹⁸ in *HPS-1*. He was homozygous for an A-to-C substitution in the -2 position of intron 17 (Fig 3), causing an 18-bp deletion (nucleotides 1,744 to 1,761) in the *HPS-1* cDNA. This 35-year-old Irish man had nystagmus and decreased visual acuity from

childhood, as well as bruising and episodes of epistaxis. He received a diagnosis of HPS at age 32, when his sister died of pulmonary fibrosis due to HPS. After age 32, his dyspnea on exertion and cough worsened gradually for 2 years, then rapidly during the year prior to admission. The patient had never smoked. On admission to the NIH Clinical Center, he had visual acuity of 20/100 in both eyes, with marked iris transillumination. His blood and urine chemistries and hematologic studies, including von Willebrand factor, were normal except for a sedimentation rate of 38 mm/h (normal, 0 to 25). Pulmonary function tests revealed a FVC 51% of predicted; FEV₁, 54%; total lung capacity (TLC), 51%; vital capacity (VC), 49%; and diffusion of the lung for carbon monoxide (DLCO), 26%. There was no response to bronchodilators. Arterial blood gases showed a pH of 7.39, PCO₂ of 31 mm Hg (normal, 35 to 48 mm Hg), PO₂ of 84 mm Hg (normal, 83 to 108 mm Hg), and oxygen saturation of 96% (normal, 94 to 98%). HRCT scan of the chest revealed diffuse interstitial fibrosis with cyst formation, corresponding to a score of 3 (Fig 4). The patient died of respiratory insufficiency 4 months after discharge.

Pulmonary Function Testing

The 38 adult HPS patients in this study displayed a normal distribution of values for FVC, FEV₁, TLC, VC, and DLCO when expressed as percent of predicted. The distributions of FVC and DLCO values

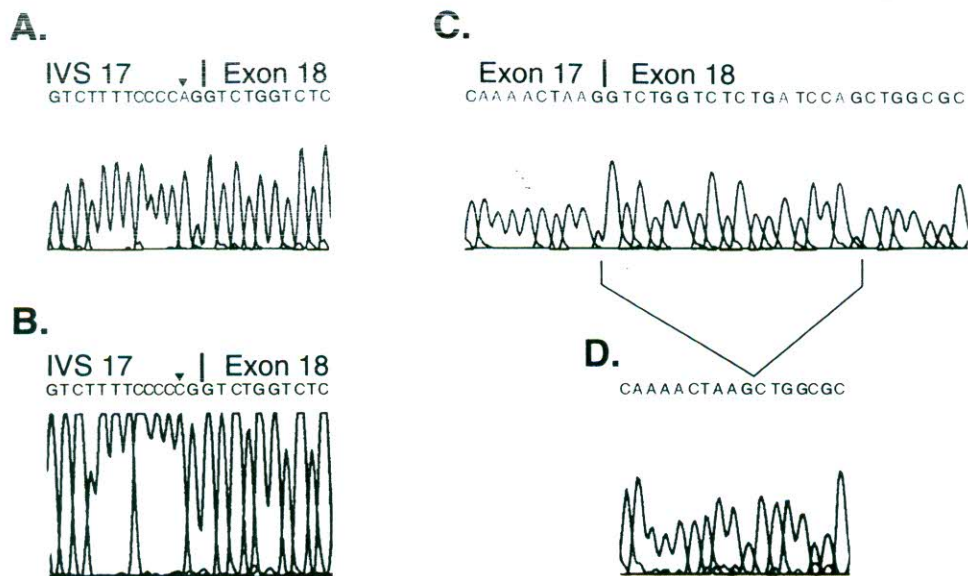


FIGURE 3. IVS 17 -2 A→C mutation in the *HPS-1* gene of the non-Puerto Rican patient. In the genomic DNA sequence of a normal individual (top left, A.) and of the patient (bottom left, B.) at the boundary between IVS 17 and exon 18 of *HPS-1*, there is an A→C substitution at the -2 position (arrowheads). The cDNA sequences of a normal individual (top right, C.) and of the patient (bottom right, D.) reveal the patient's in-frame deletion of the first 18 bp of exon 18.

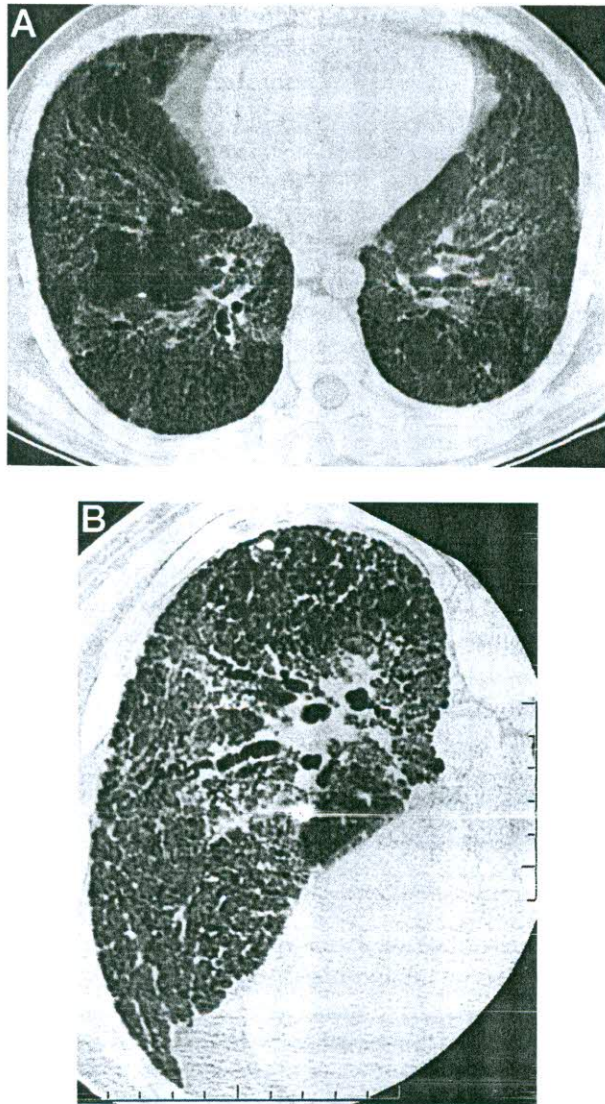


FIGURE 4. HRCT findings in a 35-year-old non-Puerto Rican patient with a homozygous mutation in *HPS-1*. *Top, A*: conventional 10-mm-thick CT section through the midthorax. Note extensive interstitial lung disease. *Bottom, B*: targeted HRCT of the left midthorax. Note improved resolution of bronchiectasis and peribronchovascular fibrosis compared with conventional CT image.

are shown in Figure 5. The mean values for each pulmonary function varied between 68 and 76% of predicted (Table 1); the range for individual values was 24 to 119%. None of the 34 patients tested showed a positive response to bronchodilators. Mean oxygen saturation was approximately 97% on room air (Table 1), with a range of 88 to 100%.

HRCT Findings

Routine chest radiographs were abnormal in 17 of 35 patients (49%) studied (Table 1), while 31 of 38 patients (82%) manifested abnormalities on CT scan

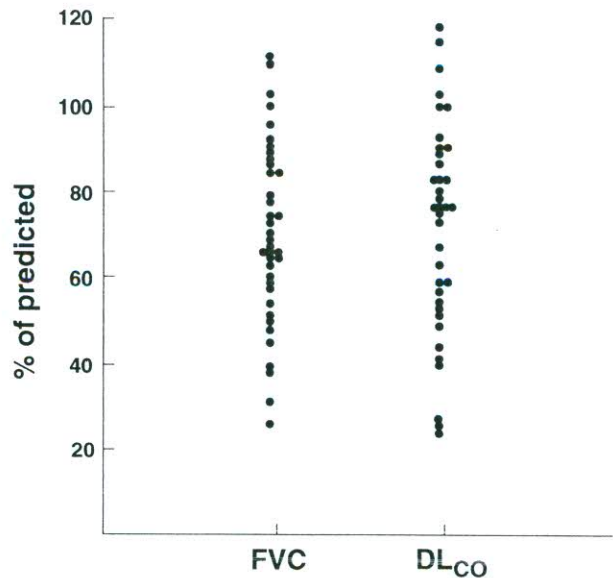


FIGURE 5. Distribution of FVC and DLCO values for HPS patients.

(HRCT score ≥ 0.5). The mean HRCT score was 1.30 (Table 1), with a range of 0 to 3.

Correlations of Pulmonary Function and HRCT Score

HRCT scores correlated inversely and reasonably well ($r = -0.66$) with FVC (Fig 2, *top, A*) and DLCO (Fig 2, *bottom, B*). An additional analysis was performed after dividing all 38 patients into groups according to their pulmonary function. Twelve patients were deemed normal (FVC $> 80\%$ of predicted), 14 mildly impaired (FVC 61 to 80%), 8 moderately impaired (FVC 41 to 60%), and 4 severely impaired (FVC $\leq 40\%$). For these four groups, mean values for FEV₁, TLC, VC, and DLCO mirrored those for FVC (Table 2). The mean age of the patients in each severity group was nearly identical. The 12 HPS patients with nearly normal pulmonary function (on average, 95% of predicted) exhibited a mean \pm SEM HRCT score that was also very close to normal, *ie*, 0.6 ± 0.2 (Table 2). However, as disease severity progressed and the FVC fell, the HRCT score increased. In the four most severely compromised patients, the mean \pm SEM HRCT score was 2.4 ± 0.4 (Table 2).

The HRCT score gave a general prediction of mortality: five of five patients with an HRCT score of 3 died of pulmonary fibrosis 1 week to 4 months after the examination. One of two patients with a score of 2.5 died 12 months after the procedure. No patients with scores of ≤ 2.0 died of pulmonary fibrosis.

Table 2—HRCT Scores at Different Levels of Pulmonary Function in Adults With Mutations in HPS-1*

Functional Impairment	No.	Age, yr	Pulmonary Function, % of Predicted					HRCT Score
			FVC	FEV ₁	TLC	VC	DLCO	
Severe (FVC ≤ 40%)	4	37 ± 1	34 ± 3	35 ± 4	42 ± 3	36 ± 4	42 ± 8	2.4 ± 0.4
Moderate (FVC 41 to 60%)	8	40 ± 2	53 ± 2	59 ± 2	51 ± 1	51 ± 3	45 ± 5	2.2 ± 0.4
Mild (FVC 61 to 80%)	14	36 ± 4	70 ± 1	78 ± 2	73 ± 2	67 ± 2	74 ± 5	1.1 ± 0.2
Negligible (FVC > 80%)	12	36 ± 3	95 ± 3	99 ± 3	95 ± 4	93 ± 3	95 ± 4	0.6 ± 0.2

*Results expressed as means ± SEM.

DISCUSSION

Recent molecular advances allow clinical evaluation of HPS patients based on their genetic loci and individual mutations. The most critical aspect of this evaluation involves the life-threatening pulmonary disease of HPS. Previous studies of pulmonary function in this disorder have included relatively few individuals,^{6,23-27} or have concentrated on pulmonary lavage findings.⁷ We performed an intensive, inpatient investigation of adults who had molecularly defined mutations in *HPS-1*, the gene responsible for HPS in nearly all Puerto Ricans and in approximately one third of non-Puerto Ricans.^{13,15,16} Our studies employed modern HRCT scanning of the chest for assessment of pulmonary fibrosis, and correlation of these results with pulmonary function tests.

Several significant findings resulted from evaluation of 38 patients with *HPS-1* mutations. First, the characteristics of these patients' pulmonary fibrosis were delineated. One prominent discovery was the enormous individual variability in pulmonary findings, as reflected in pulmonary function results (Fig 5). This was not attributable to age, as groups of HPS patients with different severities of pulmonary disease had approximately the same mean age (Table 2). Clearly, some HPS patients are more prone than others to develop pulmonary fibrosis, despite the fact that they are homozygous for exactly the same 16-bp duplication in the *HPS-1* gene. The variability among Puerto Rican HPS patients, which has also been noted with respect to hypopigmentation,²⁰ could derive from either environmental factors, such as exposure to toxins or frequent pulmonary infections, or from epigenetic phenomena. Certain modifying genes, for example, may be expressed more in some patients than in others, predisposing them to fibrosis or protecting them against it. A list of genes playing such a role might include those influencing inflammation or vesicular trafficking or providing a function redundant to that of the *HPS-1* gene product.

In any event, cross-sectional analysis of our patients indicated that the 23 individuals who developed pulmonary symptoms did so at approximately 35 years of age. By a mean age of 37 years, our total group of 38 patients had pulmonary function values approximately 70% of predicted, and the individual parameters such as the FVC, FEV₁, TLC, VC, and DLCO fell in concert as the pulmonary pathology of HPS progressed (Table 2). The pulmonary function test results were not influenced by bronchodilator therapy, and were not generally associated with oxygen desaturation. That is, for HPS patients as a group (Table 1) and for the single non-Puerto Rican patient described in detail, oxygen saturation values at rest were maintained in the normal range despite significant impairment in pulmonary function parameters. This situation has been observed in interstitial lung disease in general.²⁸ The well-compensated state of our patients may also be related to their relatively young age compared with, for example, idiopathic pulmonary fibrosis patients. However, we would expect that even our young HPS patients with impaired pulmonary function would desaturate on exercise testing.

A second result of our study is the conclusion that an HRCT scoring system, developed to evaluate pulmonary fibrosis in HPS (Fig 1), provides an excellent radiologic gauge of the extent of disease. As expected, HRCT scans were considerably more sensitive than standard chest radiographs. In addition, the severity of pulmonary fibrosis on HRCT scan was found to correlate with the degree of pulmonary dysfunction, whether assessed by FVC and DLCO (Fig 2) or by an entire battery of pulmonary function tests (Table 2). Such a correlation of HRCT scan findings with pulmonary function results is not unique to HPS; it has also been reported for fibrosing alveolitis.²⁹

Finally, the risk of pulmonary fibrosis in HPS might be associated with mutations in *HPS-1* rather than specifically with the 16-bp duplication in *HPS-1*

observed in Puerto Rican patients. In one patient who had a homozygous in intervening sequence (IVS) 17 -2 substitution causing an 18-bp deletion in exon 18, severe pulmonary fibrosis developed (Fig 4) and the patient died at 35 years of age. This mutation retained significant residual *HPS-1* messenger RNA on Northern blot analysis (data not shown), and maintained both the frame and the dileucine signal of the *HPS-1* gene product. Although the only other in-frame *HPS-1* mutation, a deletion of the three bps comprising I55, was reported to be associated with a very mild phenotype,¹⁶ our patient exhibited fatal pulmonary disease. It is possible that *HPS-1* mutations in general predispose to pulmonary involvement; whether other HPS-causing genes are associated with pulmonary disease remains to be determined.

That there exist other HPS-causing genes has become abundantly clear. Evidence for locus heterogeneity comes from both Puerto Rican¹⁹ and non-Puerto Rican patients,^{15,16} as well as the existence of 14 genetically different autosomal recessive mouse models of HPS that combine pigment dilution with a platelet storage pool deficiency.^{30,31} *Pale ear*, for example, is the murine analog of human patients with *HPS-1* mutations,^{32,33} while the *pearl* mouse, whose defect lies in the β 3A subunit of adaptor complex-3,³⁴ corresponds to a human sibship bearing "*HPS-2*" gene mutations.³⁵ The two individuals with compound heterozygous *HPS-2* mutations are not yet old enough to reveal whether mutations in this gene are associated with pulmonary fibrosis.

Progress in isolating additional HPS-causing genes, including genes involved in vesicular trafficking,³⁶ should lead to an assessment of which HPS subtypes are associated with pulmonary fibrosis and which are not. Such a determination will be of extreme prognostic value, applied both to individual patients and to group studies of pulmonary fibrosis therapies. Until some treatment of the pulmonary dysfunction of HPS becomes available, all patients should take measures to preserve their existing pulmonary function, with special emphasis on patients bearing *HPS-1* mutations. Precautions include avoidance of primary and secondary cigarette smoke and other lung toxins, prompt therapy of respiratory infections, regular exercise and a healthy diet, and prophylaxis with influenza and pneumococcal immunizations. In the future, these precautions may be deemed less essential in patients whose genotypes indicate that they are free of the risk of pulmonary fibrosis.

ACKNOWLEDGMENT: The authors appreciate the excellent work of Hilda Cardona and the other nurses of the 8 W and 9 W wards and the pulmonary function unit of the NIH Clinical Center. This study would not have been possible without the

assistance of the HPS Network and its presidents, based in Puerto Rico (Carmelo Almodovar) and the mainland United States (Donna Appell).

REFERENCES

- Hermansky F, Pudlak P. Albinism associated with hemorrhagic diathesis and unusual pigmented reticular cells in the bone marrow: report of two cases with histochemical studies. *Blood* 1959; 14:162-169
- Witkop CJ, Quevedo WC, Fitzpatrick TB, et al. Albinism. In: Scriver CR, Beaudet AL, Sly WS, et al, eds. *The metabolic basis of inherited disease*. 6th ed. New York, NY: McGraw-Hill, 1989; 2905-2947
- Summers CG, Knobloch WH, Witkop CJ, et al. Hermansky-Pudlak syndrome: ophthalmic findings. *Ophthalmology* 1988; 95:545-554
- King RA, Hearing VJ, Creel DJ, et al. Albinism. In: Scriver CR, Beaudet AL, Sly WS, et al, eds. *The metabolic and molecular bases of inherited disease*. 7th ed. New York, NY: McGraw-Hill, 1995; 4353-4392
- Witkop CJ, Krumwiede M, Sedano H, et al. Reliability of absent platelet dense bodies as a diagnostic criterion for Hermansky-Pudlak syndrome. *Am J Hematol* 1987; 26:305-311
- Garay SM, Gardella JE, Fazzini EP, et al. Hermansky-Pudlak syndrome: pulmonary manifestations of a ceroid storage disorder. *Am J Med* 1979; 66:737-747
- Harmon KR, Witkop CJ, White JG, et al. Pathogenesis of pulmonary fibrosis: platelet-derived growth factor precedes structural alterations in the Hermansky-Pudlak syndrome. *J Lab Clin Med* 1994; 123:617-627
- Schinella RA, Greco MA, Cobert BL, et al. Hermansky-Pudlak syndrome with granulomatous colitis. *Ann Intern Med* 1980; 92:20-23
- Mahadeo R, Markowitz J, Fisher S, et al. Hermansky-Pudlak syndrome with granulomatous colitis in children. *J Pediatr* 1991; 118:904-906
- Witkop CJ, Babcock MN, Rao GHR, et al. Albinism and Hermansky-Pudlak syndrome in Puerto Rico. *Bol Asoc Med PR* 1990; 82:333-339
- Wildenberg SC, Oetting WS, Almodovar C, et al. A gene causing Hermansky-Pudlak syndrome in a Puerto Rican population maps to chromosome 10q2. *Am J Hum Genet* 1995; 57:755-765
- Fukai K, Oh J, Frenk E, et al. Linkage disequilibrium mapping of the gene for Hermansky-Pudlak syndrome to chromosome 10q23.1-23.3. *Hum Mol Genet* 1995; 4:1665-1669
- Oh J, Bailin T, Fukai K, et al. Positional cloning of a gene for Hermansky-Pudlak syndrome, a disorder of cytoplasmic organelles. *Nat Genet* 1996; 14:300-306
- Bailin T, Oh J, Feng GH, et al. Organization and nucleotide sequence of the human Hermansky-Pudlak syndrome (HPS) gene. *J Invest Dermatol* 1997; 108:923-927
- Shotelersuk V, Hazelwood S, Larson D, et al. Three new mutations in a gene causing Hermansky-Pudlak syndrome: clinical correlations. *Mol Genet Metab* 1998; 64:99-107
- Oh J, Ho L, Ala-Mello S, et al. Mutation analysis of patients with Hermansky-Pudlak syndrome: a frameshift hot spot in the HPS gene and apparent locus heterogeneity. *Am J Hum Genet* 1998; 62:593-598
- Spritz RA, Oh J. *HPS* gene mutations in Hermansky-Pudlak syndrome. *Am J Hum Genet* 1999; 64:658-659
- Oetting WS, King RA. Molecular basis of albinism: mutations and polymorphisms of pigmentation genes associated with albinism. *Hum Mutat* 1999; 13:99-115

- 19 Hazelwood S, Shotelersuk V, Wildenberg SC, et al. Evidence for locus heterogeneity in Puerto Ricans with Hermansky-Pudlak syndrome. *Am J Hum Genet* 1997; 61:1088-1094
- 20 Gahl WA, Brantly M, Kaiser-Kupfer MI, et al. Genetic defects and clinical characteristics of patients with a form of oculocutaneous albinism (Hermansky-Pudlak syndrome). *N Engl J Med* 1998; 338:1258-1264
- 21 Sambrook J, Fritsch EF, Maniatis T. *Molecular cloning: a laboratory manual*. 2nd ed. Plainview, NY: Cold Spring Harbor Laboratory Press, 1989
- 22 Fulmer JD, Roberts WC, von Gal ER, et al. Small airways in idiopathic pulmonary fibrosis: comparison of morphologic and physiologic observations. *J Clin Invest* 1977; 60:595-610
- 23 Shimizu K, Matsumoto T, Miura G, et al. Hermansky-Pudlak syndrome with diffuse pulmonary fibrosis: radiologic-pathologic correlation. *J Comput Assist Tomogr* 1998; 22:249-251
- 24 Horowitz, ID. Dyspnea in a 30-year old Hispanic man with albinism. *Chest* 1995; 108:1158-1160
- 25 Reynolds SP, Davies BH, Gibbs AR. Diffuse pulmonary fibrosis and the Hermansky-Pudlak syndrome: clinical course and postmortem findings. *Thorax* 1994; 49:617-618
- 26 Hoste P, Williams J, Devriendt J, et al. Familial diffuse interstitial pulmonary fibrosis associated with oculocutaneous albinism. *Scand J Respir Dis* 1979; 60:126-134
- 27 White DA, Walker Smith EJ, Cooper Jr JD, et al. Hermansky Pudlak syndrome and interstitial lung disease: report of a case with lavage findings. *Am Rev Respir Dis* 1984; 130:138-141
- 28 Keogh BA, Crystal RG. Clinical significance of pulmonary function tests: pulmonary function testing in interstitial pulmonary disease; what does it tell us? *Chest* 1980; 78:856-865
- 29 Terriff BA, Kwan SY, Chan-Yeung MM, et al. Fibrosing alveolitis: chest radiography and CT as predictors of clinical and functional impairment at follow-up in 26 patients. *Radiology* 1992; 184:445-449
- 30 Jackson IJ. Homologous pigmentation mutations in human, mouse and other model organisms. *Hum Mol Genet* 1997; 6:1613-1624
- 31 Swank RT, Novak EK, McGarry MP, et al. Mouse models of Hermansky-Pudlak syndrome: a review. *Pigment Cell Res* 1998; 11:60-80
- 32 Gardner JM, Wildenberg SC, Keiper NM, et al. The mouse pale ear (ep) mutation is the homologue of human Hermansky-Pudlak syndrome. *Proc Natl Acad Sci USA* 1997; 94:9238-9243
- 33 Feng GH, Bailin T, Oh J, et al. Mouse pale ear (ep) is homologous to human Hermansky-Pudlak syndrome and contains a rare "AT-AC" intron. *Hum Mol Genet* 1997; 6:793-799
- 34 Feng L, Seymour AB, Jiang S, et al. The β 3A subunit gene (Ap3b1) of the AP-3 adaptor complex is altered in the mouse hypopigmentation mutant pearl, a model for Hermansky Pudlak syndrome and night blindness. *Hum Mol Genet* 1999; 8:323-330
- 35 Dell'Angelica EC, Shotelersuk V, Aguilar RC, et al. Altered trafficking of lysosomal proteins in Hermansky-Pudlak syndrome due to mutations in the β 3A subunit of the AP-3 adaptor. *Mol Cell* 1999; 3:11-21
- 36 Shotelersuk V, Gahl WA. Hermansky-Pudlak syndrome: models for intracellular vesicle formation. *Mol Genet Metab* 1998; 65:85-96